Hemangioma of the parotid

Lester D.R. Thompson, MD

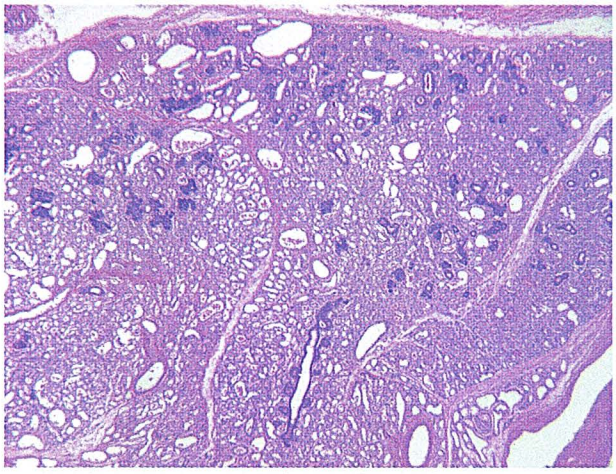

Figure 1. Low-power view shows a benign hemangioendothelioma (hemangioma) intersecting the normal architecture of the parotid gland (darkly stained blue areas with central lumina).

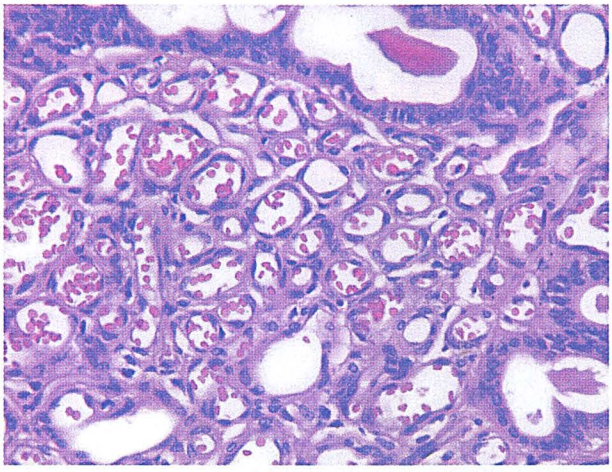

Figure 2. High-power view shows one and two layers of endothelial cells with slightly spindle-shaped nuclei lining red blood cell-filled clear spaces. Uninvolved acini are seen at the top and in the right lower corner.

Hemangiomas are benign tumors of endothelial cell origin (benign hemangioendotheliomas). They are the most common salivary gland tumor in children younger than 1 year of age, accounting for 90% of cases. Hemangiomas in adults are uncommon. The characteristic features of hemangiomas are the rapid enlargement of a unilateral (usually on the left), compressible, bluish mass shortly after birth, particularly in girls. Hemangiomas are not associated with any syndrome.

Macroscopically, these tumors are lobular, dark, and as large as 8 cm in maximum dimension. Histologically, they are characterized by an unencapsulated intralobular growth with replacement of salivary gland acini by capillary-sized vessels (vessels without muscle walls). These vessels are marked by compressed vascular lumina and increased cellularity (figure 1). The cellularity can be so great that it obscures the vascular lumina altogether. The capillaries are lined with two or more layers of spindle-shaped endothelial cells that feature ample eosinophilic cytoplasm (figure 2). Their nuclei contain clear nuclear chromatin (vesicular nuclei; open chromatin). Mitotic figures are frequent, but atypical forms are not seen. Vascular arborization and anastomoses are not observed. Although peri- and intraneural invasion can be seen, it is not an indicator of tumor behavior. A reticulin stain outlines the vessels in which the endothelial cells proliferate. The vascular origin of the neoplasm is confirmed by positive factor VIII-related antigen, CD34, or CD31 immunohistochemical reactions. Whereas lymphangioma is included in the differential diagnosis, separation from malignant hemangioendothelioma or angiosarcoma is more important. Anastomosing vascular channels lined with remarkably atypical endothelial cells herald angiosarcoma, which is rare in infants.

Although complete surgical excision has been advocated, a conservative wait-and-see approach provides an opportunity for spontaneous regression and an overall decrease in size. Malignant transformation does not occur. If surgery is needed later in childhood, there will be a lower likelihood of possible facial nerve damage.

Suggested reading

Lack EE, Upton MP. Histopathologic review of salivary gland tumors in childhood. Arch Otolaryngol Head Neck Surg 1988;114:898-906.

From the Department of Endocrine and Otorhinolaryngic–Head and Neck Pathology, Armed Forces Institute of Pathology, Washington, D.C.